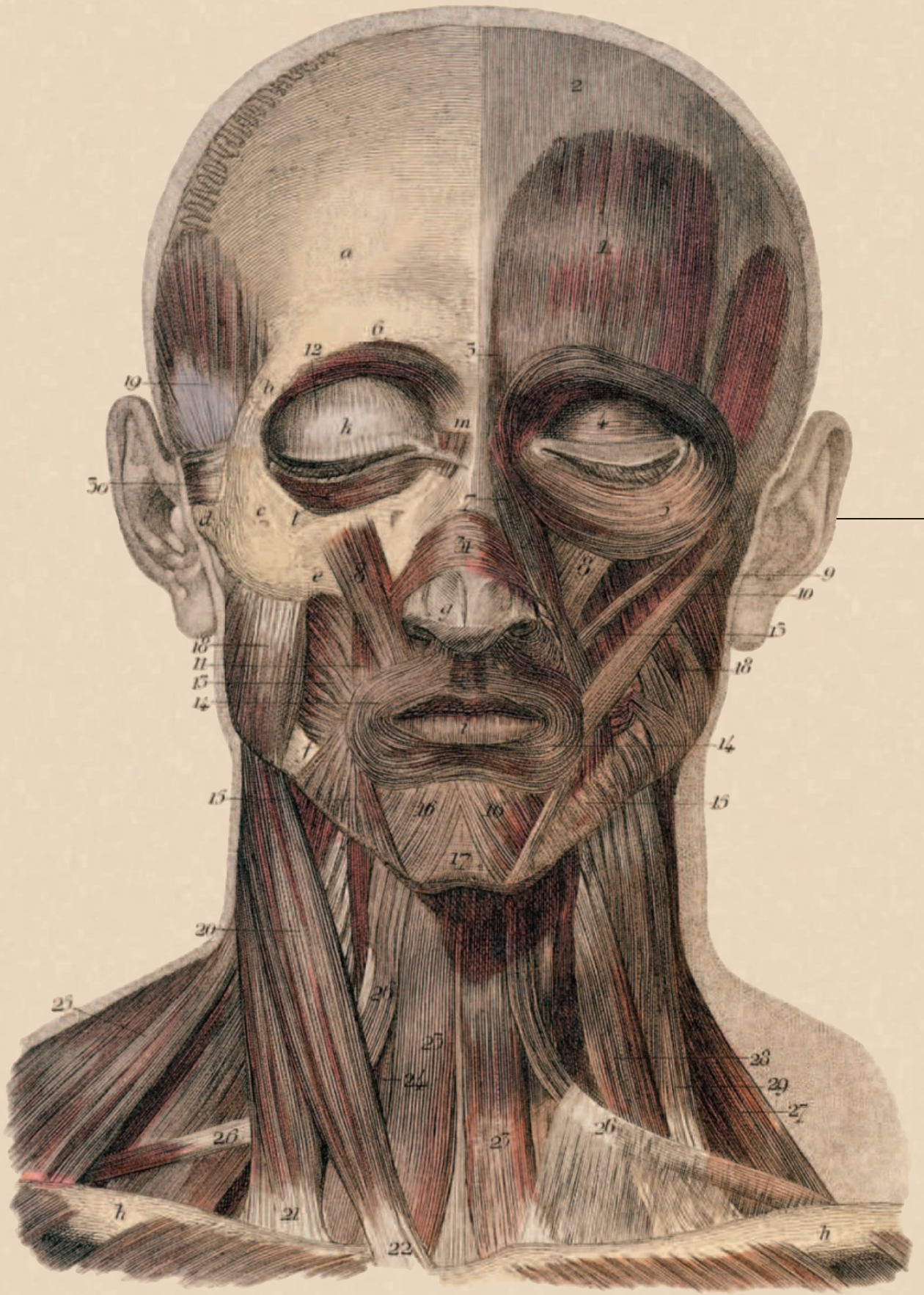


Fig. 1.



SURGERY

of the Head and Neck

Mary Sutton, CST, CFA

This article is one of a series that will discuss head and neck surgeries from an otolaryngology perspective. Most of these surgeries involve cancer, and often involve portions of the alimentary or respiratory tracts that must not be compromised. The desired outcome is excision of the tumor, which may present some cosmetic problems for the patient. If excision is not feasible, then any palliative procedure may include bypassing the

tumor to allow the patient to get nourishment or a proper route of respiration.

Surgeons in other specialties may assist the otolaryngologist with these procedures, such as a total laryngopharyngectomy with a gastric pull-up or repair of a defect with a pedicle or free flap, such as a mandibulectomy with a fibular free flap.

Part one examines the anatomy of the head and neck, various types of dissection and the related instrumentation.

Neck anatomy

The neck contains major communication routes from the head to the rest of the body. It holds the spinal cord, the air and food passages, major nerve pathways that include several cranial nerves and their branches, and the major blood vessels that flow between the head and the heart.

Musculature

The strap muscles of the neck connect the larynx and associated structures, such as the hyoid bone, with the sternum anteriorly. There are also muscles that connect the hyoid bone with the base of the tongue, mandible, and the styloid process of the temporal bone.

The strap muscles of the neck connect the larynx and associated structures, such as the hyoid bone, with the sternum anteriorly. There are also muscles that connect the hyoid bone with the base of tongue, mandible, and the styloid process of the temporal bone. The digastric muscle has one belly, which extends from the mastoid to the hyoid and then ascends to the anterior mandible about at the midline. The sternocleidomastoid muscle divides the neck into anterior and posterior triangles. The posterior triangle is mostly the musculature of the spinal cord; whereas, the anterior triangle is composed of most of the major vessels and structures of the neck. The anterior neck may be divided into smaller triangles for dissection purposes.

The anterior and posterior bellies of the digastric muscle form the submandibular triangle. Both anterior bellies of the digastrics form the submental triangle, which is the midline of the neck. The vascular or carotid triangle is inferior to the digastric and hyoid. The omohyoid muscle, which is important in dissection landmarks, runs from the hyoid to the scapula, almost perpendicular to the sternocleidomastoid muscle (SCM). The platysma muscle extends from the clavicle to the acromion process of the scapula, the deltoid fascia, and the pectoralis major to the lower border of the mandible.

Innervation

Several major nervous structures course throughout the neck. Knowledge of the course of these nerves is important in any dissection of the neck or neck structures. The marginal mandibular branch of the facial nerve (VIIth cranial) dips below the mandible into the fascia above the submandibular gland, before ascending upward to innervate the corner of the mouth. The cervical branch of the facial nerve innervates the platysma, the stylohyoid muscle, and the posterior belly of the digastric.

The vagus nerve travels inferior to the carotid within the carotid sheath. In the chest, the vagus sends a branch back to the larynx. This branch, the recurrent laryngeal nerve, ascends along the tracheoesophageal (TE) groove and enters the larynx to innervate the true vocal cords. Great care is taken to identify and preserve this nerve in head and neck surgeries, especially thyroidectomy and parathyroidectomy, as damage to this nerve will cause vocal cord paralysis with its associated pathology.

The spinal accessory nerve (XIth cranial) travels from the skull base to innervate the SCM and the trapezius muscle, usually above the level of the carotid bifurcation below the digastric muscle. The hypoglossal nerve (XIIth cranial) travels from the skull base to cross the carotid artery, usually above the bifurcation, and then ascends to innervate the tongue. Often during neck dissections, there are two areas where knowledge of the course of the hypoglossal nerve is important—the carotid bifurcation and the area where the nerve ascends through tissue inferior to the submandibular gland. When performing a laryngectomy, care is taken not to injure the hypoglossal nerve, as it passes close to the lateral horn of the hyoid bone.

The lingual nerve is identified in submandibular gland excision as it travels superior and deep to the gland. The phrenic nerve travels in the posterior neck to the diaphragm from cervical roots 3-5. The brachial plexus also starts in the posterior neck, running from C5 to T1. There is also a cervical sympathetic chain, which travels in the carotid sheath.

Vascularity

The major artery to the head is the carotid, which branches in the neck to the external and internal carotid arteries. The internal carotid has no branches in the neck. The branches of the external carotid artery in the neck include: the superior thyroid, ascending pharyngeal, facial, lingual, occipital, postauricular, and the internal maxillary arteries.

The carotid artery courses through the neck within its own carotid sheath. Also contained within the sheath are the vagus nerve and the internal jugular vein. The external jugular vein is more lateral in the neck. There are also anterior jugular veins, which run along the midline of the neck along the strap muscles.

Pharynx, larynx, esophagus, and trachea

The pharynx, larynx, esophagus, and trachea also are major structures of the neck. The pharynx and larynx are closely associated in the anatomy of the neck until they separate, approximately at the level of the cricoid cartilage, to become the esophagus and trachea.

The thyroid gland resides anterior and lateral to the trachea, below the strap muscles. Blood supply to the thyroid is from both superior and inferior poles, but care is taken to identify the recurrent laryngeal nerve before sacrificing any structures around the thyroid. Paired parathyroid glands are usually found on the posterior aspect of the thyroid gland, but may be found as inferiorly as the mediastinum.

Lymphatics

Cervical lymph nodes are divided into several levels for dissection. These levels are determined by the anatomic structures of the tissue in which they reside. The importance of levels for neck dissections is due to the recent studies of the lymphatic metastasis from different head and neck tumors. It has been found that, based on the location of the tumor, there is a specific lymphatic flow and, therefore, a greater propensity for the lymph nodes in that flow zone to become metastatic.

Tumor staging (TNM)

In head and neck cancer, as well with other cancers, there is a tumor staging system that identifies the size of the tumor, lymph node involvement, and metastasis. The tumor is identified in three ways: a "T" class, which represents the size and depth of the tumor; an "N" class, which represents the site of nodal metastasis, if any, the number of nodes involved, and the size of these nodes; and an "M" class, which represents metastasis to distant tissues.

The "T" class is as follows:

- T₀ Unknown primary tumor
- T₁ 0 cm to 2 cm
- T₂ 2 cm to 4 cm
- T₃ 4 cm to 6 cm
- T₄ Greater than 6 cm
- T_x Primary tumor cannot be assessed

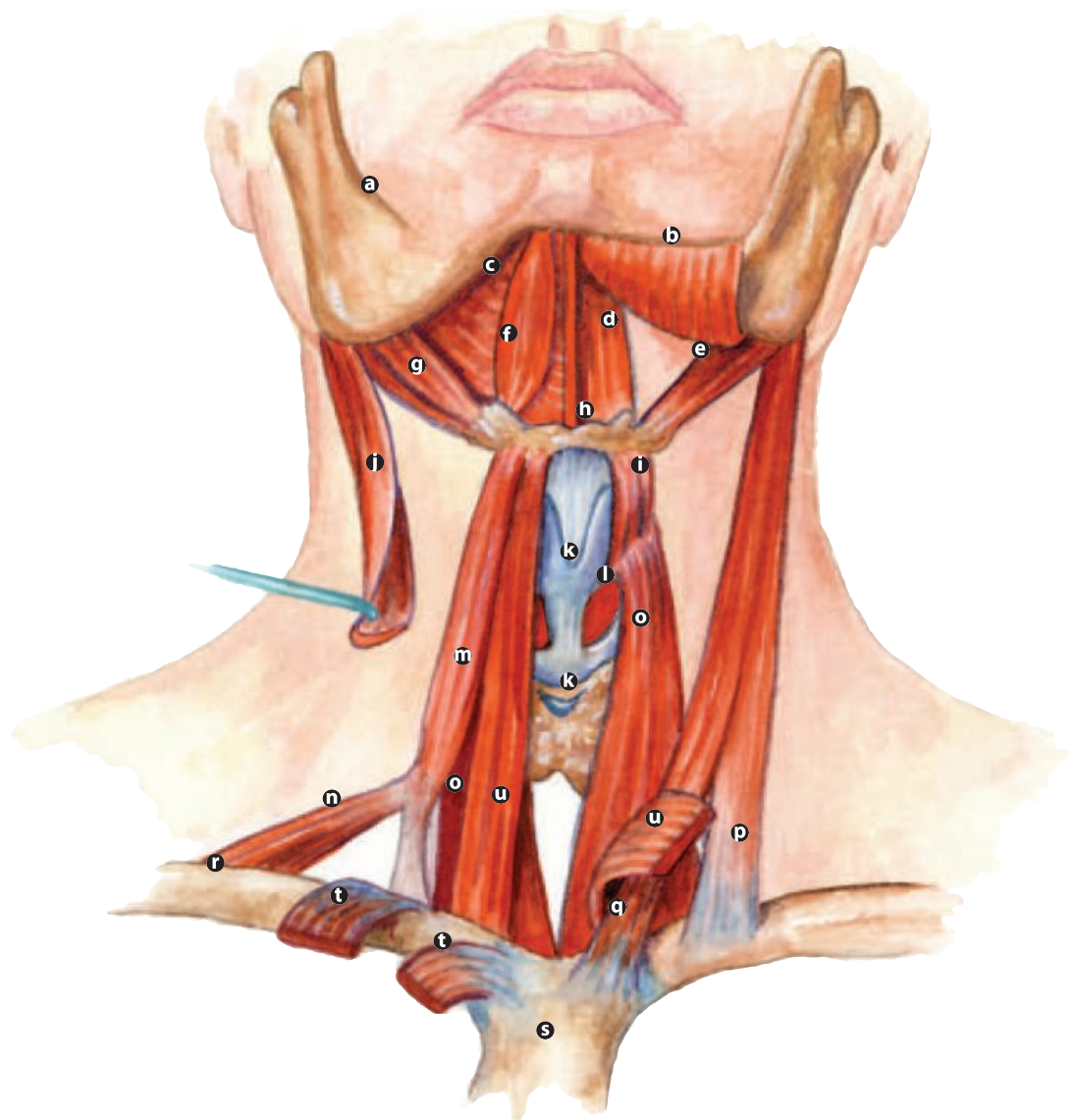
The "N" class is as follows:

- N₀ No lymph node metastasis
- N₁ Single lymph node, less than 3 cm on the same side as the tumor
- N_{2a} Single lymph node, 3-6 cm on the same side as the tumor
- N_{2b} Multiple nodes, none greater than 6 cm, same side
- N_{2c} Bilateral or opposite nodes, none greater than 6 cm
- N₃ Metastasis in a node greater than 6 cm
- N_x Nodes cannot be assessed (usually due to a node biopsy)

The "M" class is as follows:

- M₀ No distant metastasis (cancer has not spread to distant body structures)
- M₁ Distant metastasis (cancer has spread to distant body structures)
- M_x Distant metastasis cannot be assessed

Tumor staging is usually done from the patient's CT scan, but the surgeon may perform whatever appropriate surgical procedure is needed to view the primary tumor. The surgeon will also palpate the neck to feel for enlarged lymph nodes. When staging laryngeal tumors, since the vocal cord isn't 6 cm or greater, the tumor would be staged according to the surface area of the vocal cord consumed by tumor, whether it crosses over the midline and how far onto the opposite cord.



- a Mandible
- b Mylohyoid (*cut and reflected*)
- c Mylohyoid
- d Geniohyoid
- e Stylohyoid
- Digastric {
 - f Anterior belly
 - g Posterior belly
- h Hyoid bone
- i Thyrohyoid
- j Sternocleidomastoid (*cut*)
- k Cartilages of larynx
- l Cricothyroid
- Omoxyoid {
 - m Superior belly
 - n Inferior belly
- o Sternothyroid
- Sternocleido-
mastoid {
 - p Clavicular head
 - q Sternal head
- r Clavicle
- s Sternum
- t Cut heads of sternocleidomastoid
- u Sternohyoid
- v Sternohyoid

Level I lymph nodes are the nodes within the submental triangle (level Ia), and those found within the submandibular triangle (level Ib). Obviously, since the submental triangle is mid-line, there would be only one specimen for level Ib for both sides of the neck (eg if performing a bilateral neck dissection).

Level II lymph nodes are the upper jugular nodes. The anatomical boundaries are the upper third of the jugular vein and adjacent spinal accessory nerve, from the carotid bifurcation inferiorly to the skull base superiorly. Laterally, the border is the sternocleidomastoid muscle, and the medial border is the lateral border of the stylohyoid muscle.

Level III lymph nodes are the middle jugular nodes. These lymph nodes reside in the middle third of the jugular vein from the carotid bifurcation superiorly to the junction of the omohyoid muscle, with the jugular vein inferiorly. The lateral boundary is the posterior border of the sternocleidomastoid muscle. The medial boundary is the lateral border of the sternohyoid muscle.

Level IV lymph nodes are the lower jugular nodes. Boundaries of level IV are the lower third of the jugular vein from the omohyoid muscle superiorly to the clavicle inferiorly. The lateral boundary is the posterior border of the sterno-

cleidomastoid muscle, and medially the lateral border of the sternohyoid muscle.

Level V lymph nodes are the posterior triangle nodes. Boundaries of level V are the anterior border of the trapezius muscle laterally, the posterior border of the sternocleidomastoid muscle medially, and the clavicle inferiorly.

Level VI lymph nodes are the anterior cervical nodes. These lymph nodes are usually taken when removing the specimen, usually the larynx. Level VI comprises the lymph nodes surrounding the midline structures of the neck, from the hyoid bone superiorly to the suprasternal notch inferiorly. The lateral border of level VI is the carotid sheath on each side of the neck.

Instrumentation, supplies, and equipment

Various types of neck dissection will be discussed after a general overview of the instrumentation, supplies, and equipment needed.

Instrumentation

Most hospitals have some type of neck dissection tray for head and neck cases. It is important that these trays contain several fine-tip tonsil clamps or Scanlon clamps (which are sometimes called baby Burlisher clamps). Green thyroid retractors are important retractors for neck trays as well as US Army (Army/Navy), baby Richardson, double skin hooks, vein retractors, nerve hooks, and rakes. A bipolar cord and tips, which is usually the bayonet type, are essential. Extra Allis clamps, Lahey clamps, and fine mosquitoes are usually included in the typical neck set. Many surgeons utilize a baby Yankauer suction tip; however, it is advisable to include a larger Yankauer tip and assorted Frazier tips as well.

(Tech tip: It is always a good habit to have a tracheotomy set in the room when doing any kind of major neck dissection, especially with removal of a tumor.)

Supplies

Supplies needed for a neck dissection depend on whether the dissection is performed independently or if it is performed in conjunction with the removal of a tumor. It is important to have

several packs of X-ray detectable 4" x 4" sponges opened on the field as they are used during the dissection. Normal supplies, such as laps, electrosurgical pencil and suction tubing, should be opened. Suture is surgeon specific but the following are recommended as routine.

- Large silk on a cutting needle to retract the neck flaps and secure the drains
- Various sizes of silk ties and stick ties
- Absorbable suture to close the incision
- Staples to close the skin

A drain should be available; most surgeons use a 10 mm flat drain with a bulb. This is the surgeon's preference, but he or she may use two drains, one on each side of the neck, so be prepared. Some surgeons like a nerve stimulator to ensure they have located major nerves within the neck. If a radical neck dissection is being performed, the surgeon may take a dermal graft to protect the carotid artery. Skin graft supplies should be available in this situation.

Equipment

Normal operating room equipment, with the addition of headlights, is needed for neck dissections. There should be a minimum of two headlights, one for the surgeon and one for the assistant. A bipolar machine, if not part of the electrosurgical unit, must be present.

Dissection types

Neck dissections are performed either in conjunction with the removal of a head and neck tumor, or after radiation therapy to shrink the size of a neck tumor. There are several types of neck dissections: radical, modified radical, and selective. For many years, radical neck dissection was the only surgery performed for head and neck cancer patients with nodal metastasis. It has only been within the last 20 years that the modified radical neck dissection was performed to protect the patient from the morbidity involved with radical neck dissection. Now, studies have shown that certain patients may only need a selective neck dissection.

Radical

Radical neck dissection involves the removal of all cervical lymph node groups, extending from the body of the mandible to the clavicle, the lateral border of the sternohyoid muscle, the contralateral anterior belly of the digastric muscle, and the anterior border of the trapezius muscle. All levels of lymph nodes are excised, as well as the spinal accessory nerve, the internal jugular vein, and the sternocleidomastoid muscle.

Indications for radical neck dissection are extensive lymph node metastases and/or extension beyond the capsule of the lymph node(s) to involve the spinal accessory nerve and the internal jugular vein.

A high morbidity results from a radical neck dissection. Morbid outcomes include:

- Cosmetic deformity due to loss of normal neck contour
- Major functional impairment of the neck due to the loss of the sternocleidomastoid muscle
- Increased risk of scar band formation and resultant neck contracture
- Shoulder drop with decreased abduction, and external rotation of the shoulder due to the loss of the spinal accessory nerve

Major morbidity is rare. However in the unfortunate situation of having bilateral radical neck dissections performed at the same time, the sacrifice of both jugular veins leads to cerebral edema and bilateral blindness immediately. The long-term morbidity is persistent facial and laryngeal swelling. If bilateral radical neck dissections must be performed, the surgeon usually operates about six weeks apart to reduce the risk of blindness and cerebral edema. The long-term morbidity would still exist.

There are two basic types of incisions for neck dissections, including radical neck dissections. The type of incision chosen is based upon what other surgery might be performed along with the neck dissection. If no other surgery is scheduled or if the other procedure is done in the mouth with no outside incision, the apron flap incision would be used.

The apron flap incision consists of an incision, usually from mastoid tip to mastoid tip, passing about two finger widths above the sternal notch. If only one side of the neck is to be dissected, the surgeon may modify the apron flap incision by ending the incision slightly past the midline of the neck.

The other incision is the Schobinger incision. This incision would be used for cases where the surgeon was splitting the lip to allow access into the mouth for better exposure, or if the mandible was being transected or split. The Schobinger incision follows the line of the mandible about two finger widths below the mandible, going up the chin to split the lip (if necessary). A second limb of the incision is made following the line of the sternocleidomastoid muscle to just above the clavicle.

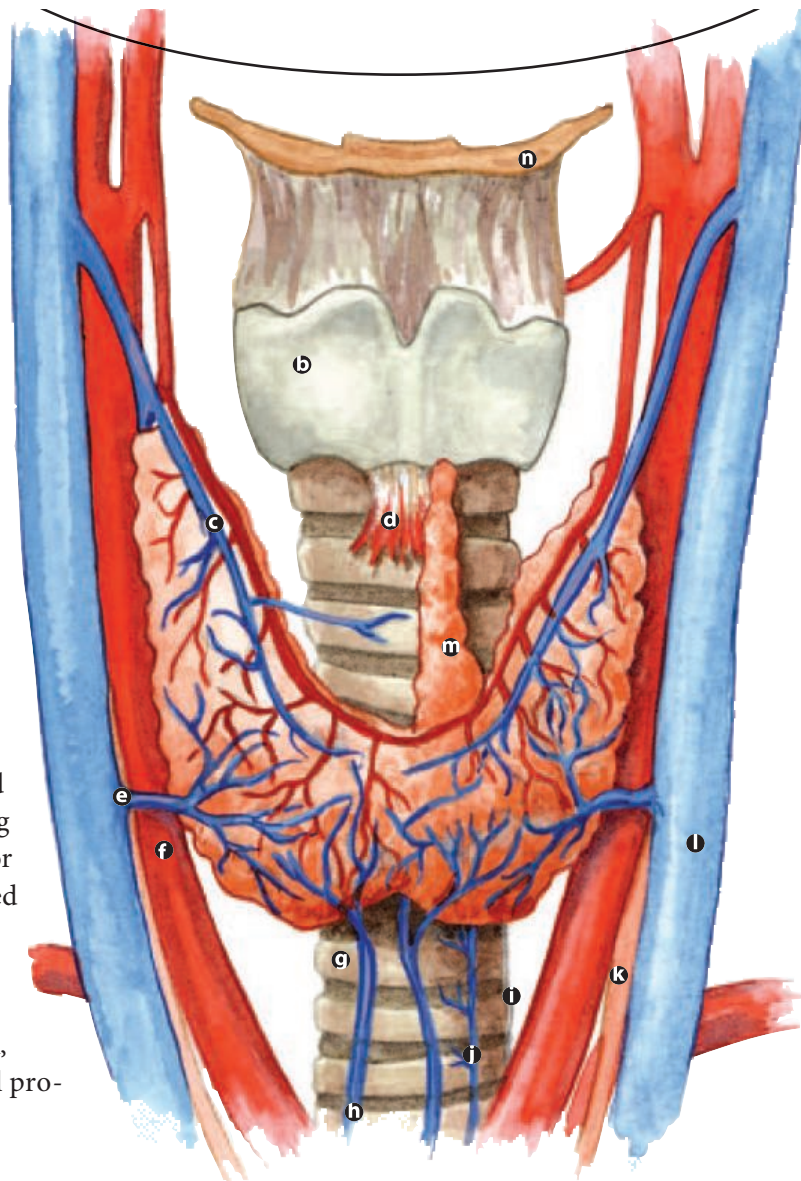
For neck dissections, the patient is placed in the supine position on the operating table with the neck extended. The affected side is turned away from the anesthesia provider, or if bilateral neck dissections are being performed, the table is usually turned so the right side is away from the anesthesia provider. The patient is prepped and draped.

The appropriate incision is made, and the skin flap is developed. Care is taken to leave the platysma muscle with the flap, as it promotes healing. The submandibular gland is identified and dissected out. The XIIth cranial nerve and the lingual nerve are identified below the gland and preserved. The duct of the submandibular gland is identified and transected.

The digastric muscle is followed to the midline of the neck, and the fatty tissue at the midline is dissected from the two bellies of the digastric. The posterior belly of the digastric is followed, and tissue is dissected out along the way. The sternocleidomastoid muscle is released from its superior attachment, and the tissue is dissected away from the floor of the neck along the sympathetic chain. Care is taken to identify the phrenic nerve and the superior portion of the brachial plexus and leave them intact. The inferior attachments of the sternocleidomastoid muscle are released.

The inferior aspect of the internal jugular vein is identified and dissected. Several heavy clamps, like Crile or Mixter, are used to transect the jugular vein. Heavy silk stick ties are used along with heavy silk ties to make sure that the vein is properly ligated. The vein is dissected away from the carotid sheath superiorly and then ligated. The rest of the neck tissue is dissected to the midline of the neck and the specimen is removed en bloc.

Some surgeons will use a dermal graft to cover the carotid artery for protection. The graft is most often taken from the thigh. The wound is irrigated and hemostasis is achieved. Bleeding vessels are coagulated, and one or two Jackson-Pratt drains are used to drain the wound. The wound is closed and dressed appropriately. Care is taken postoperatively not to overextend the neck, as the carotid artery is not well protected.



- a mandible
- b thyroid cartilage
- c superior thyroid artery and vein
- d cricothyroid ligament
- e middle thyroid vein
- f common carotid artery
- g trachea
- h inferior thyroid vein
- i esophagus
- j recurrent laryngeal nerve
- k vagus nerve
- l internal jugular vein
- u pyramidal lobe of thyroid
- o hyoid bone

Modified radical

Modified radical neck dissection is the en bloc removal of the lymph node-bearing tissue from one side of the neck, including levels I through V. The dissection extends from the mandible to the clavicle, the lateral border of the sternohyoid muscle to the anterior border of the trapezius. There is preservation of one or more of the following: internal jugular vein, spinal accessory nerve, and sternocleidomastoid muscle. (In the discussion of the selective technique later, all structures will be preserved.)

Indications for modified radical neck dissections are probable or grossly visible lymph node disease that is not directly infiltrating or fixed to the jugular vein, spinal accessory nerve, or ster-

nocleidomastoid muscle. If there is infiltration of one of these structures, the structure would be removed and the others preserved. This would prevent some of the morbidity of a radical neck dissection.

The morbidity of the modified radical neck dissection is dependent on the structures removed. Most patients experience the loss of the submandibular gland on the operative side. Some patients may have a paresthesia of the spinal accessory nerve, which leads to weakness in the shoulder and is often temporary. This is often due to retracting the nerve.

In the case of the modified radical neck dissection, the patient is supine with neck extend-

ed. The affected side is turned away from the anesthesia provider. The patient is prepped and draped. The same surgical procedure as the radical neck dissection is followed up to transecting the sternocleidomastoid muscle. In the modified radical neck dissection, the sternocleidomastoid muscle is dissected away from the tissue, which runs between it and the carotid sheath. The muscle is then retracted laterally and the spinal accessory nerve is identified superiorly.

The nerve is freed from the surrounding tissue and is gently retracted away in order to dissect out the tissue running between the sternocleidomastoid muscle and the superior internal jugular vein. This area is often referred to as the “bloody triangle,” because it is a very small area in which blood vessels are hard to locate and coagulate.

After the tissue in this area is dissected, it is brought under the nerve and is kept attached to the rest of the tissue as the dissection continues. The branch of the spinal accessory nerve, which innervates the trapezius muscle, is identified in order to be preserved. The tissue is dissected to the anterior border of the trapezius then followed upward along the carotid sheath. The carotid artery and vagus nerve are identified, and the tissue is dissected upward toward the internal jugular vein.

The tissue is dissected off the internal jugular vein sharply with a #15 blade. Care is taken to identify the branches of the vein, which will be ligated as the dissection continues along the vein. The XIIth cranial nerve is also identified as it crosses over the bifurcation of the carotid artery and makes its turn upward into tissue to be dissected free. There are some facial veins, which run along this area as well, so this tissue is clamped, cut, and ligated with free ties. After freeing the tissue along the vein and the nerve, the tissue is dissected to the midline of the neck and transected. The wound is irrigated, and hemostasis is achieved.

When doing a left neck dissection, the integrity of the thoracic duct should be verified by having the anesthesia provider perform aValsalva maneuver. (See History of Surgery, April

2005.) If chyle is detected, the duct must be identified and ligated. Any bleeding is stopped and one or two Jackson-Pratt drains should be used to drain the wound. The wound is closed and dressed appropriately.

Selective

Selective neck dissections are defined as the en bloc removal of one or more lymph node groups at risk for harboring metastatic cancer. These dissections are performed on patients who have no lymph node metastasis (N_0), but who are at risk for early lymph node metastasis. The levels removed depend on the location of the primary lesion and its known pattern of spread. The types of selective neck dissections are: supraomohyoid, lateral, posterolateral, and anterior compartment. Although a discussion of types follows, the author will not discuss the operative procedures, since they are nearly identical to that of a modified radical neck dissection—the only difference being the anatomy.

Supraomohyoid neck dissection is the removal of levels I, II, and III. If the nodes in level IV are removed, it is referred to as an extended supraomohyoid neck dissection. Indications for a supraomohyoid neck dissection include patients with an oral cavity cancer who are at risk for nodal disease. These tumors, especially from the tongue or the floor of the mouth, have a higher metastasis rate, regardless of the size of the tumor. If the patient has tongue cancer, the level IV lymph nodes are removed.

Elective supraomohyoid neck dissections may be done on the contralateral neck for patients with tumors of the floor of the mouth, ventral surface or midline of the tongue, where there are no indications for postoperative radiation therapy.

Lateral neck dissection is the en bloc removal of levels II, III, and IV. Nodal disease associated with cancers of the oropharynx, hypopharynx, and larynx is an indication for lateral neck dissections. Because most of the primary tumors in these areas are midline in the neck and have bilateral nodal drainage, bilateral lateral neck dissections are performed.

A posterolateral neck dissection is defined as the en bloc removal of levels II, III, IV, and V. This neck dissection also includes the removal of the suboccipital and postauricular nodes, and is usually associated with skin cancer and soft tissue carcinomas. The location of the primary disease is usually in the posterior scalp, nuchal ridge, occiput, or posterior upper neck. With these cancers, it is important to remove the subdermal fat and fascia between the lymph nodes and the primary disease to prevent metastasis arising in the cutaneous soft tissue.

The final selective neck dissection is the anterior compartment dissection, which is the en bloc removal of level VI lymph nodes. Indications for this dissection are for cancers arising in the thyroid, hypopharynx, cervical trachea, cervical esophagus, and laryngeal tumors that extend below the glottis. The boundaries of this dissection bilaterally are the carotid sheaths, the hyoid bone, and the sternal notch. If parathyroid glands are identified, they must be reimplanted. Often this dissection is done when taking out the primary tumor, as with a laryngectomy.

Conclusion

The anatomy of the neck, the types of dissection and the related instrumentation are all important background information for understanding head and neck surgeries from an otolaryngology perspective. A review of the various stages of cancer helps the surgical technologist relate the seriousness of the disease with the related procedure. The upcoming articles in this series will discuss specific procedures, including thyroidectomy and parathyroidectomy and surgeries of the larynx.

About the author

Mary Sutton, CST, CFA, is currently an instructor at Concorde Career Institute in Jacksonville, Florida. When she can, she is still a surgical first assistant for vitreoretinal physicians. She was certified as a CST in 1984 and as a CFA in 1994. Sutton has been a member of AST since 1984 and served as vice president of the Florida State Assembly from 1999-2003. She served on the

AST's national Board of Directors from 1996 to 2000 and currently serves on the LCC-ST Board of Directors.

References

1. *An Atlas of Head and Neck Surgery*, 3rd ed. Lore JM, ed. Philadelphia: WB Saunders; 1988.
2. Chaffee EE and Lytle IM. *Basic Physiology and Anatomy*, 4th ed. Philadelphia: Lippincott; 1980.
3. Gray H. *Gray's Anatomy*, 15th ed. Chancellor Press; 1994.
4. Martini R. Chapter 11: The Muscular System. In: *Fundamentals of Anatomy and Physiology* [online]. Prentice Hall; 2000. www.prenhall.com/bookbind/pubbooks/martinidemo/chapter11/medialib/CH11/html/ch11_4_1.html (accessed 5/16/05)
5. Taber's Online 3.0. [registration required] www.tabers.com (accessed 5/7/05)
6. Cancer Facts. Staging: Questions and Answers. National Cancer Institute. cis.nih.gov/fact/5-32.htm
7. Association of Surgical Technologists. *Study Guide to Accompany Surgical Technology for the Surgical Technologist: A Positive Care Approach*, 2nd ed. Junge T, ed. Clifton Park, NY: Thompson Delmar Learning; 2004.